The Impact of Artificial Intelligence on Radiology

Ronald M. Summers, M.D., Ph.D.

Senior Investigator

Imaging Biomarkers and CAD Laboratory
Radiology and Imaging Sciences
NIH Clinical Center, Bethesda, MD

github.com/rsummers11
www.cc.nih.gov/drd/summers.html

Disclosures

- Patent royalties from iCAD, ScanMed
- Research support from Ping An & NVidia
- Software licenses to Philips, Ping An.

What is AI?

- When a machine mimics "cognitive" functions that humans associate with other human minds, such as "learning" and "problem solving”
- In medical imaging, AI is used for diagnosis, prediction, opportunistic screening, quantitation, treatment planning, …

Source: Wikipedia

Why is AI so exciting right now?

- Series of computer science developments that enabled neural networks with many layers to be trained
- Development of inexpensive GPUs to accelerate deep neural network training
- Success of deep neural networks at solving hard problems such as object recognition in natural world images

Two Paradigms for Learning

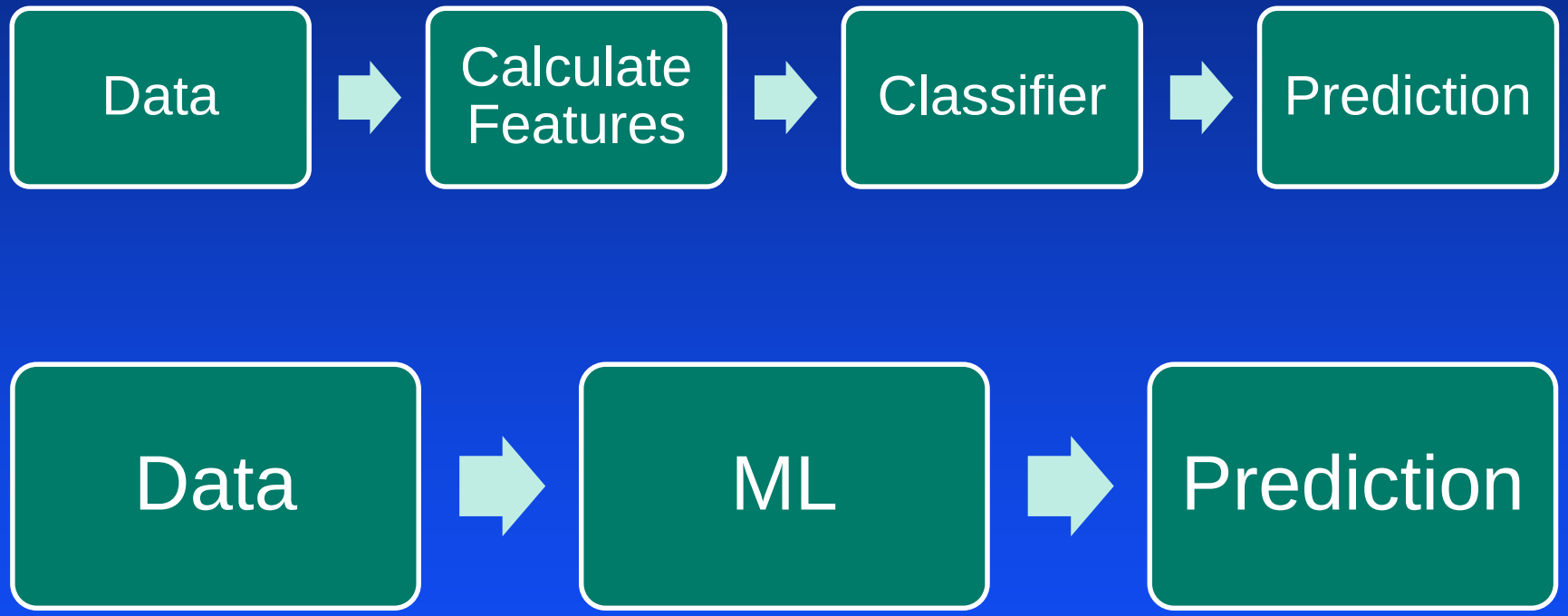

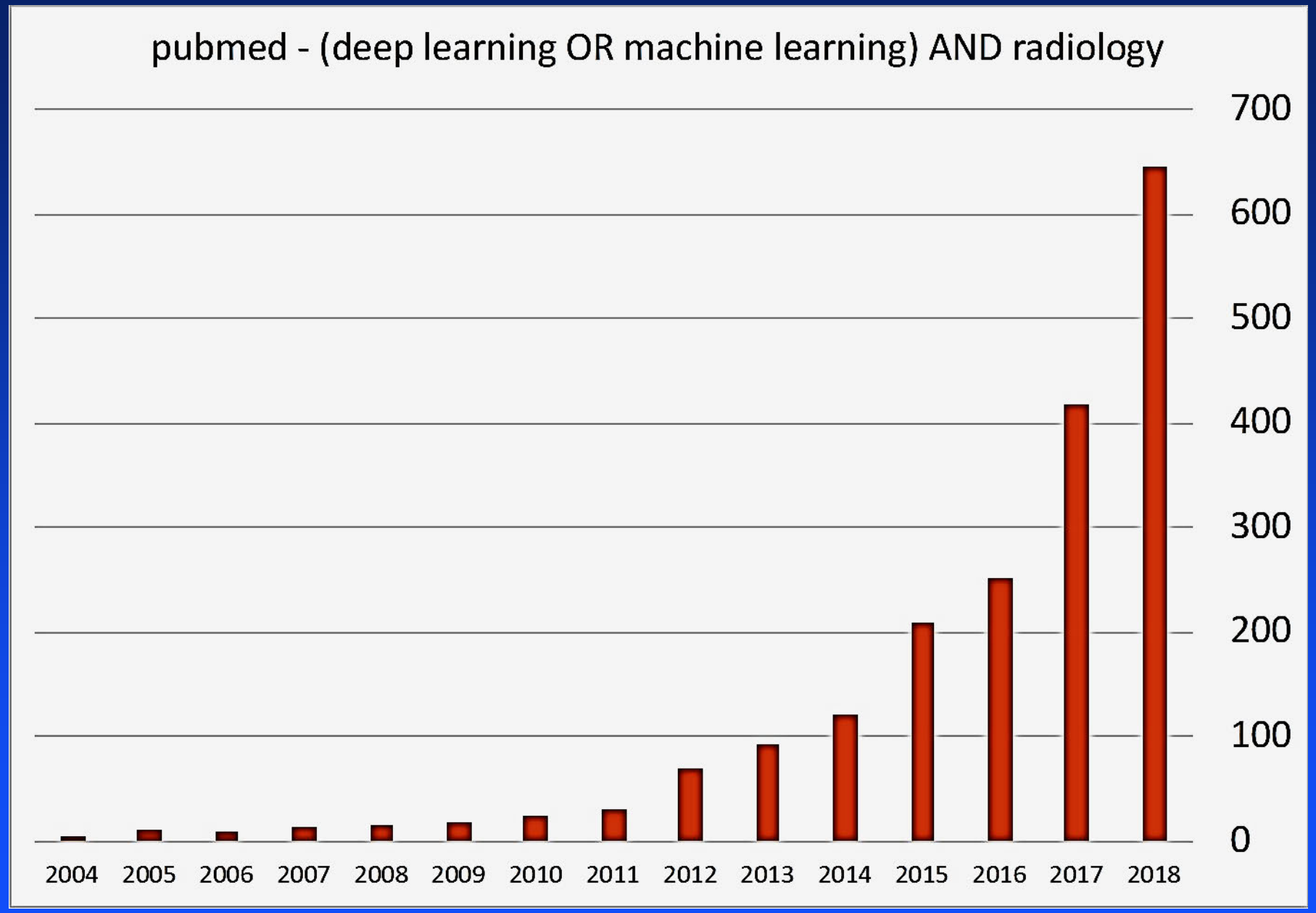
pubmed - (deep learning OR machine learning) AND radiology
700
600
500
400
300
200
100
0
2004
2005
2006
2007
2008
2009
2010
2011
2012
2013
2014
2015
2016
2017
2018

Increases in Sensitivity with Deep Learning

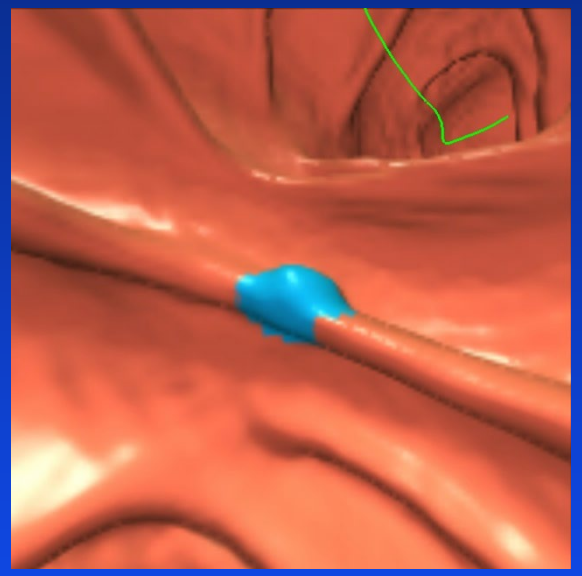

6 – 17%

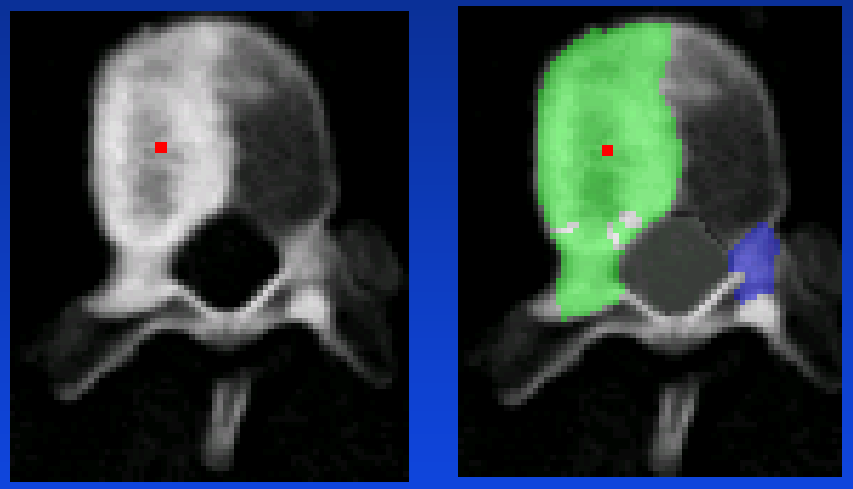

13%

34%

Summers et al. Gastroenterology 2005; Roth et al. IEEE TMI 2015;
J Burns, J Yao et al. RSNA 2011; Radiology 2013; I Nogues et al. RSNA 2016

Lymph Node CT Dataset

- doi.org/10.7937/K9/TCIA.20
- TCIA CT Lymph Node
- 176 scans, 58 GB
- Annotations, candidates, ma

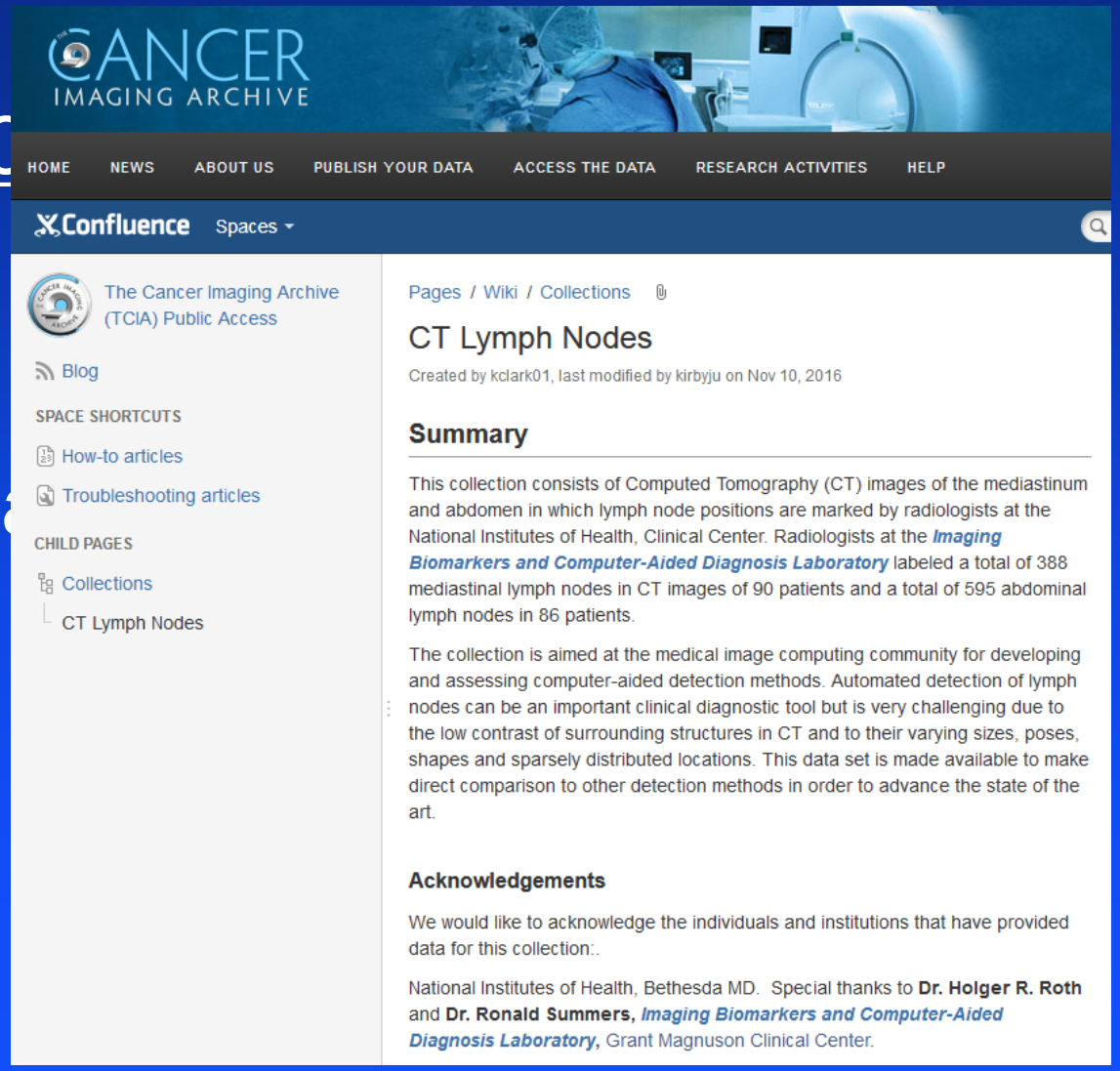

Colitis Detection

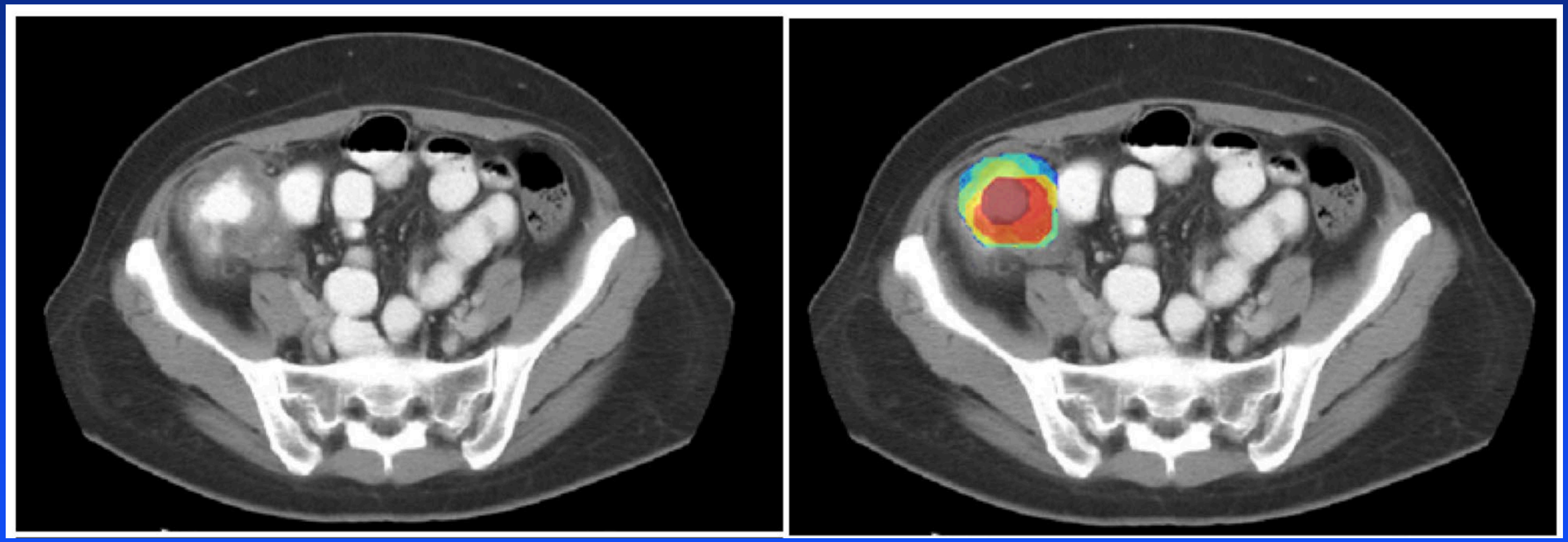

J Liu et al. Medical Physics 2017

Colitis Detection

80 patients
80 controls

93.7% Sensitivity
95.0% Specificity
0.986 AUC

J Liu et al. Medical Physics 2017

Pancreas Segmentation

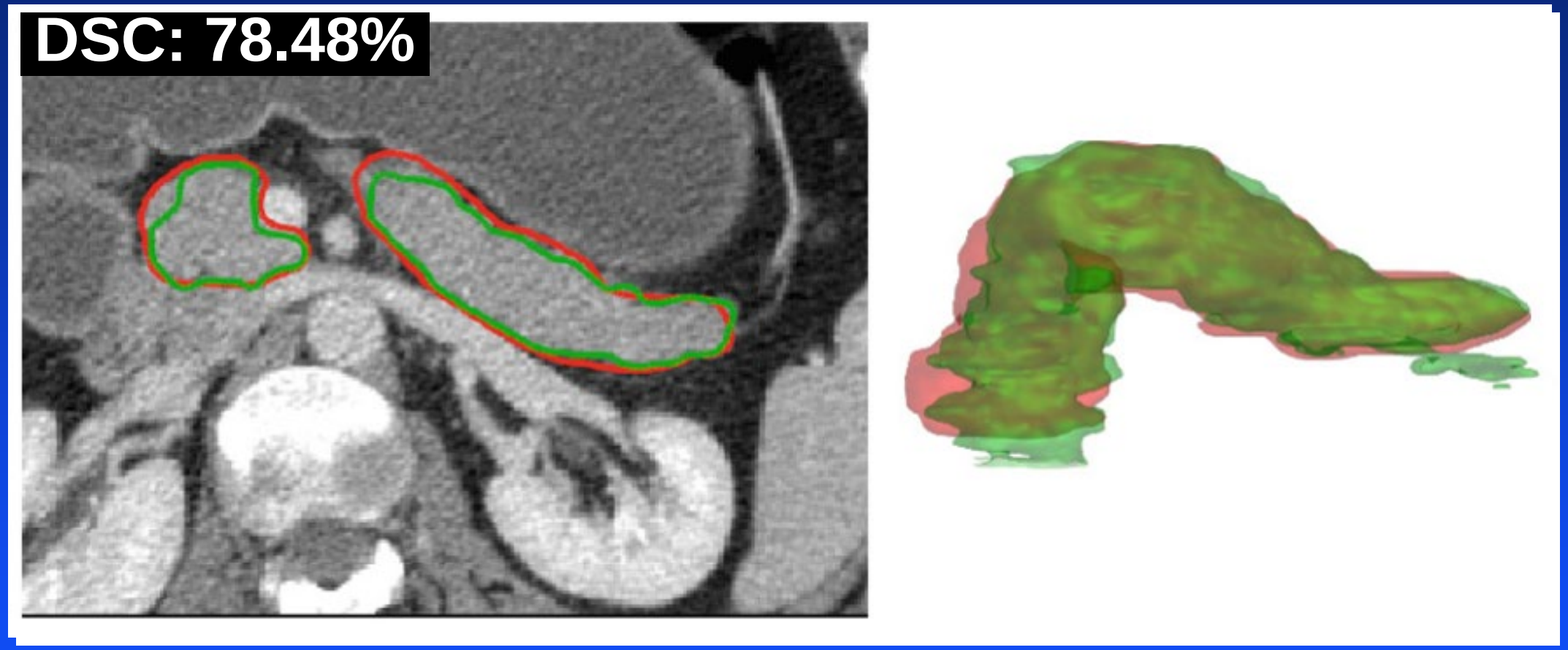

H Roth et al., MICCAI 2016

Pancreas CT Dataset

- doi.org/10.7937/K9/TCIA.2016.tNB1kqBU
- TCIA CT Pancreas
- 82 scans, 10 GB

Prostate Cancer Detection

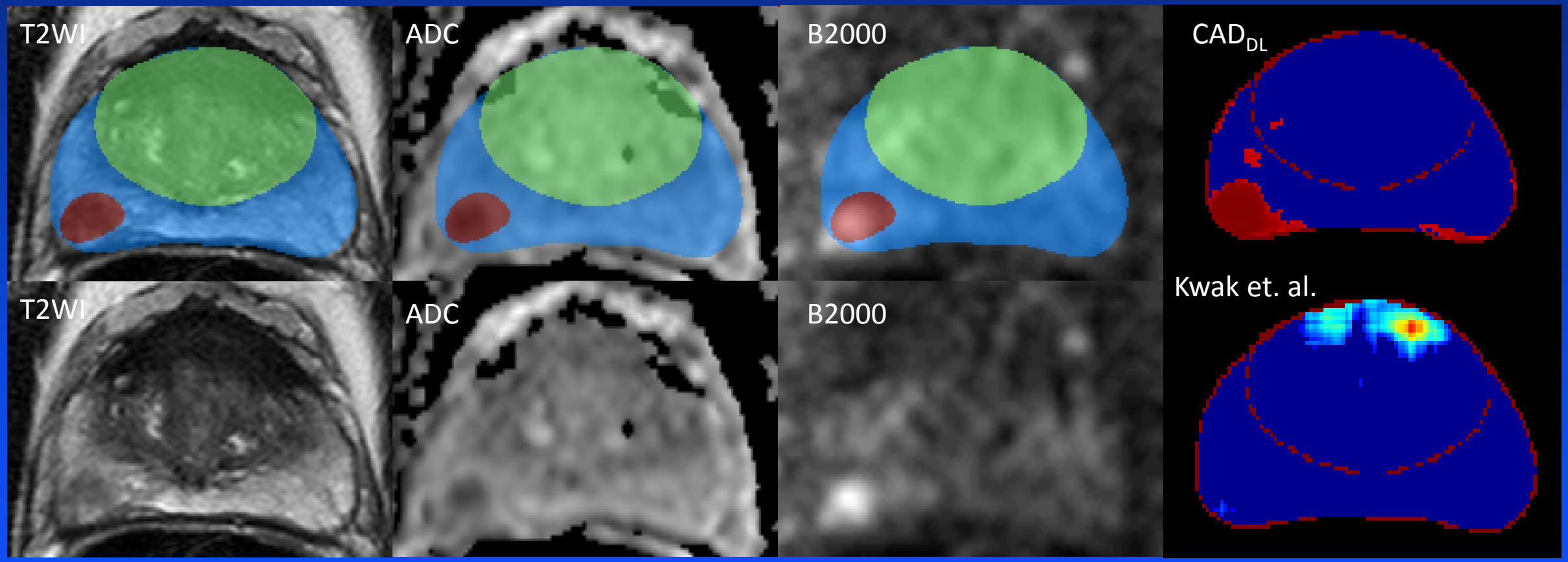

Tsehay et al. SPIE MI 2017

Prostate Cancer Detection: Observer Study

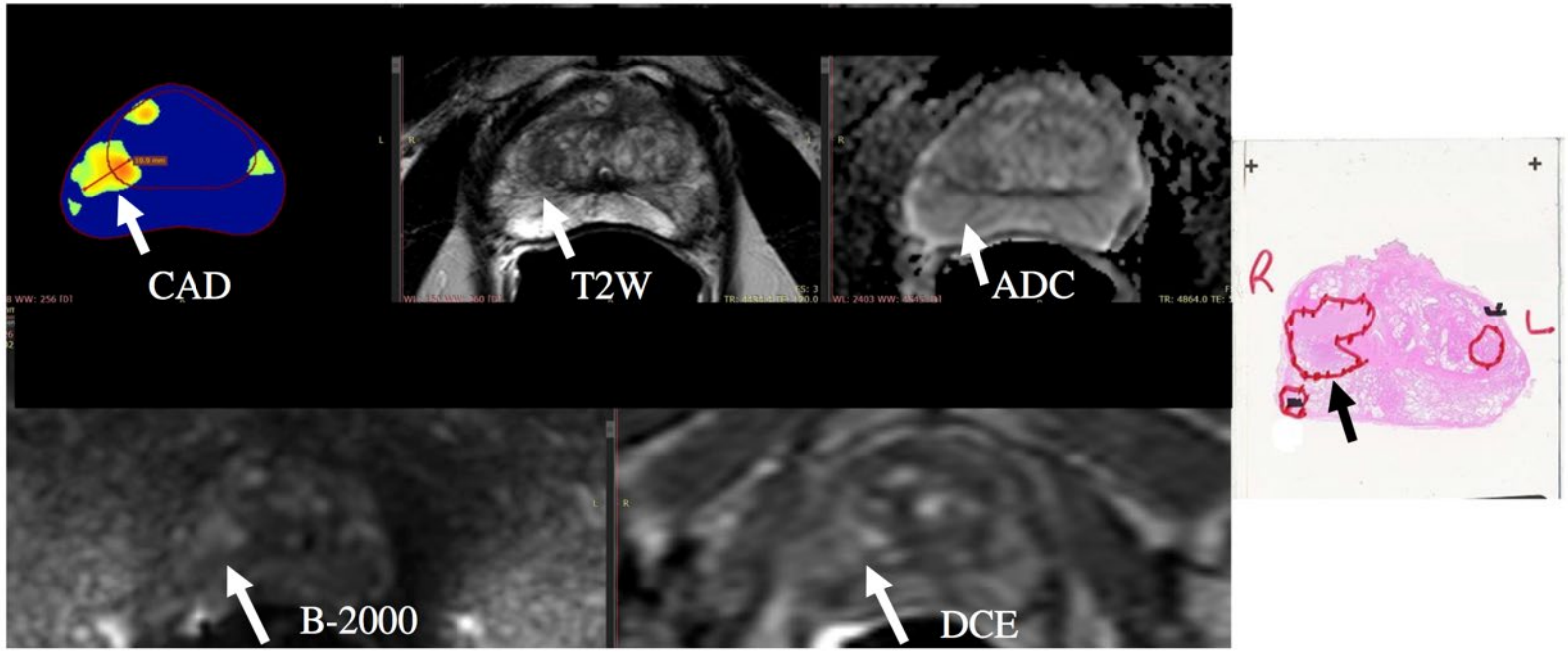

PI-RADS Score For Each Reader

Reader	1	2	3	4	5	6	7	8	9
CAD	1	1	2	4	ND	2	4	ND	2
MRI	ND	ND	ND	3	3	ND	ND	ND	3

*ND= Not Detected

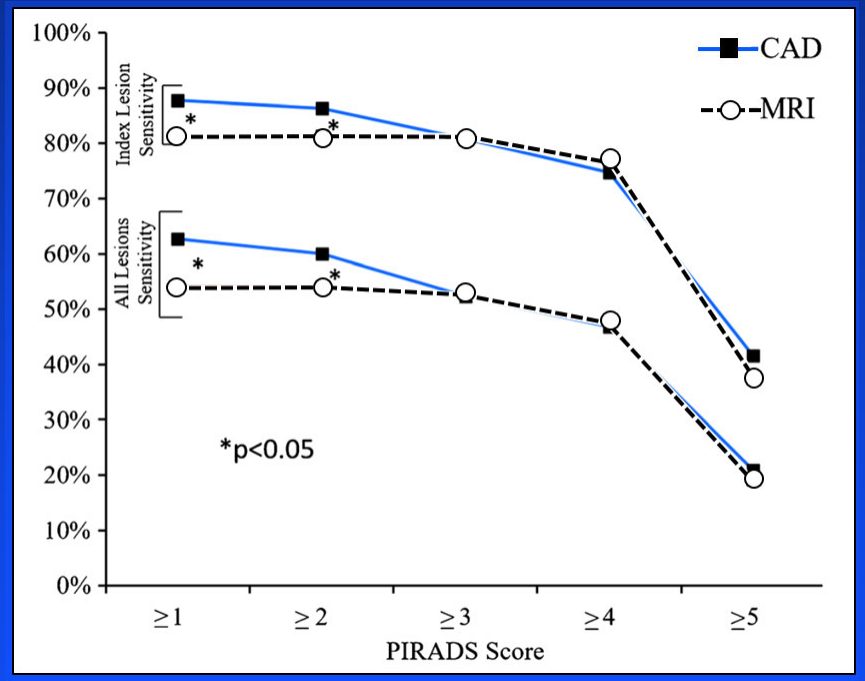

Greer et al. Eur Radiol 2018

Atherosclerosis Detection & Segmentation: Whole Body Calcium Scoring

>=130HU

DICE=0.41

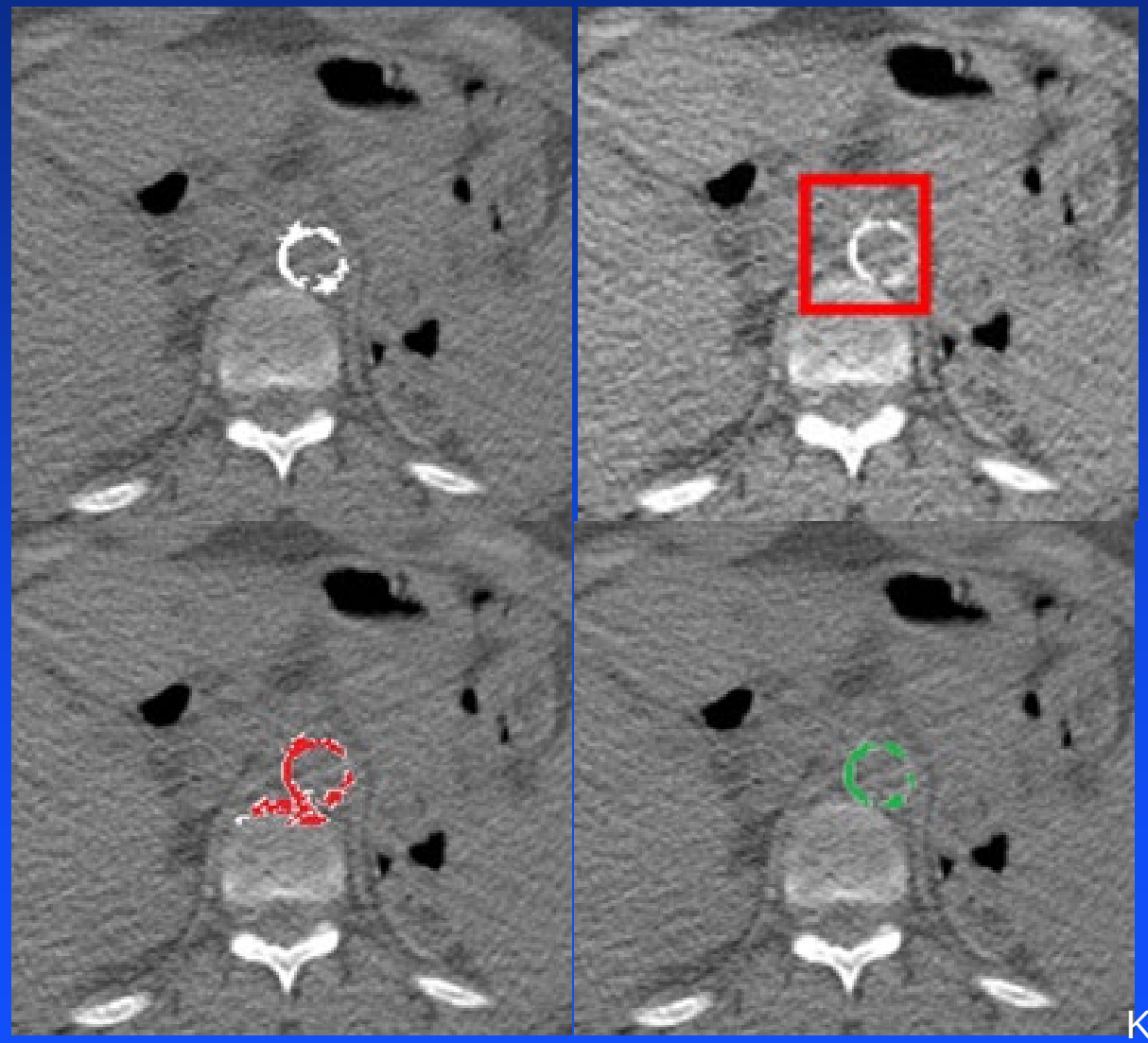

HED

DICE=0.82

K Chellamuthu, J Liu et al., ISBI 2017

Pathologic Lung Segmentation

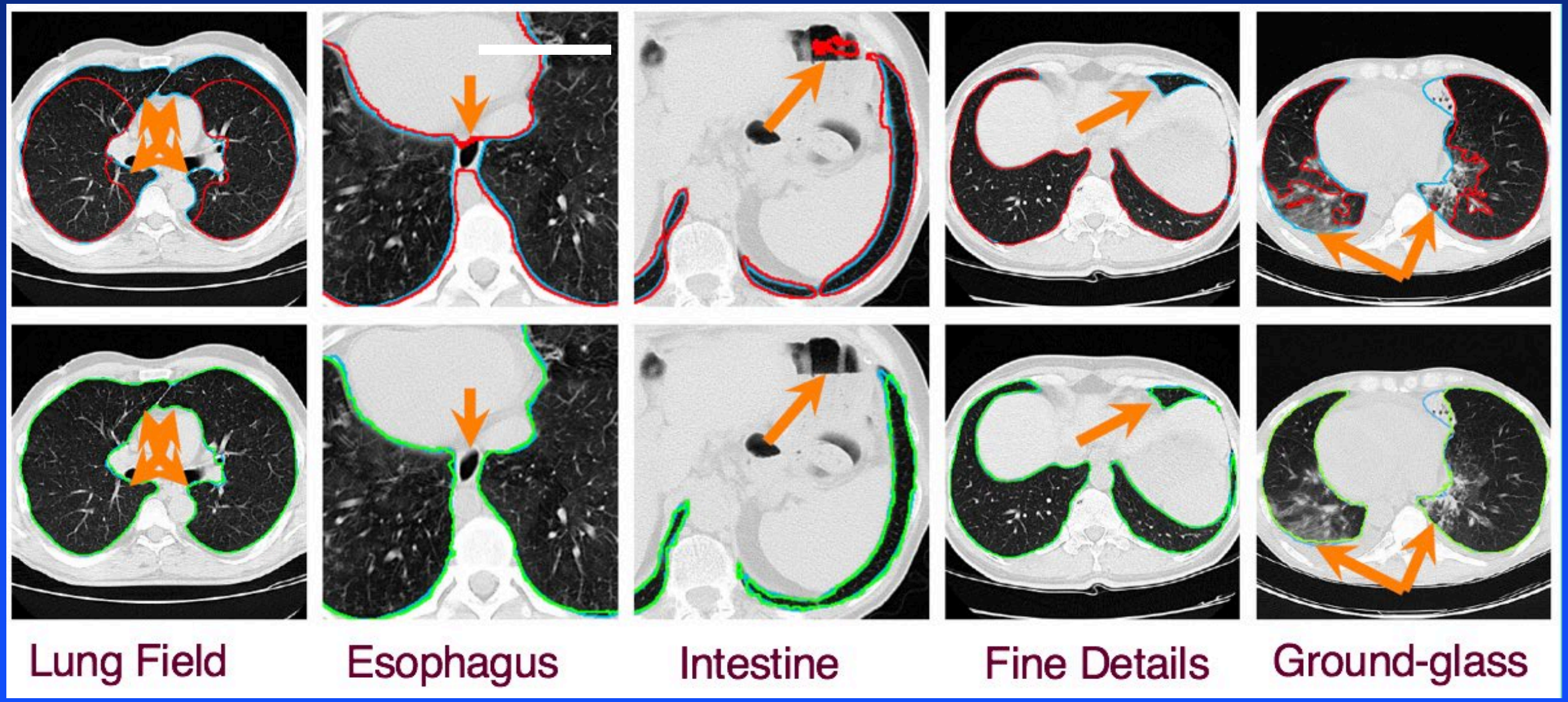

A Harrison et al. MICCAI 2017

Segmentation: ILD Label Propagation

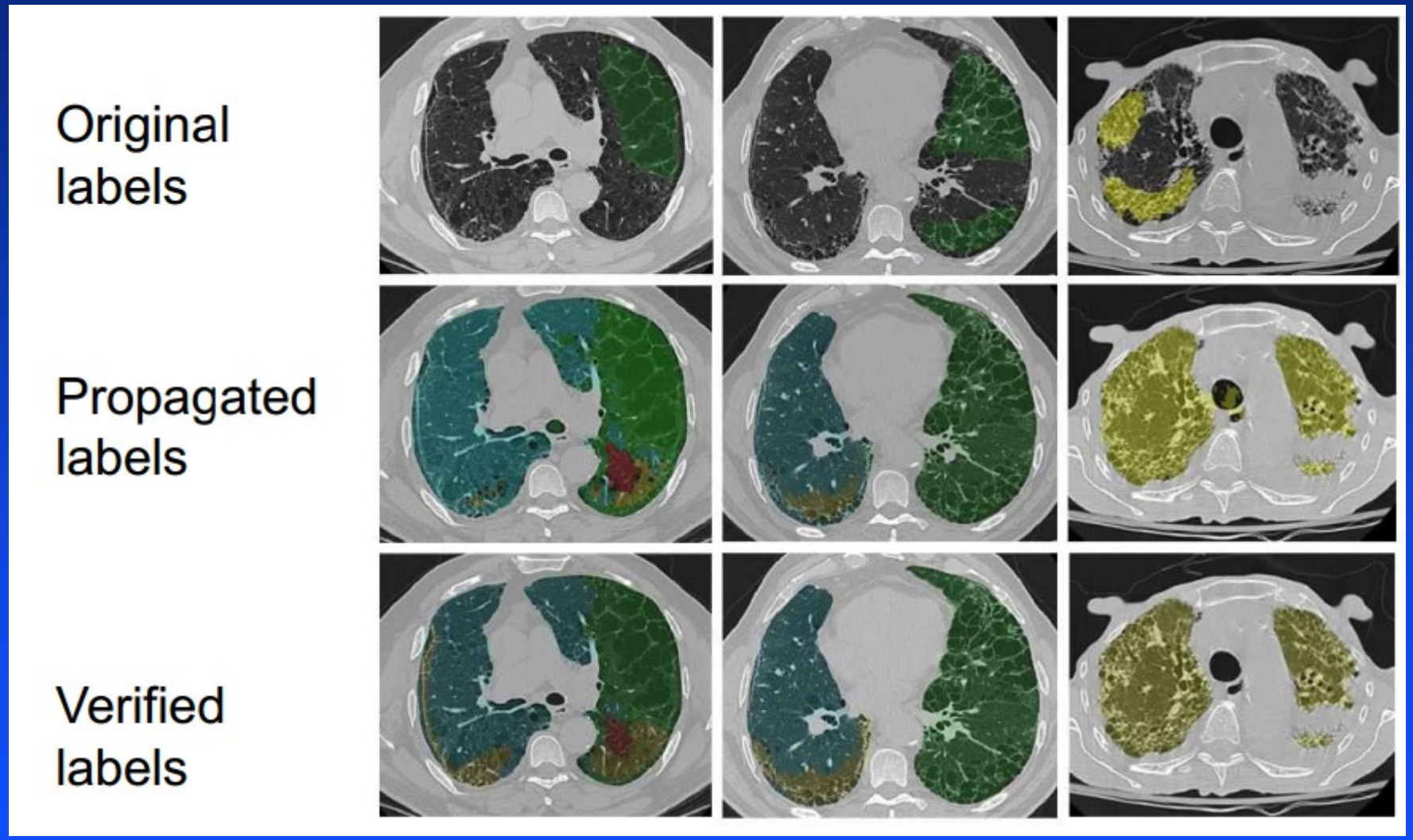

Healthy
Ground Glass
Micronodule
Honeycomb
Emphysema

Gao et al. IEEE ISBI 2016

Muscular Dystrophy: Muscle Segmentation

Manual Automated Manual Automated

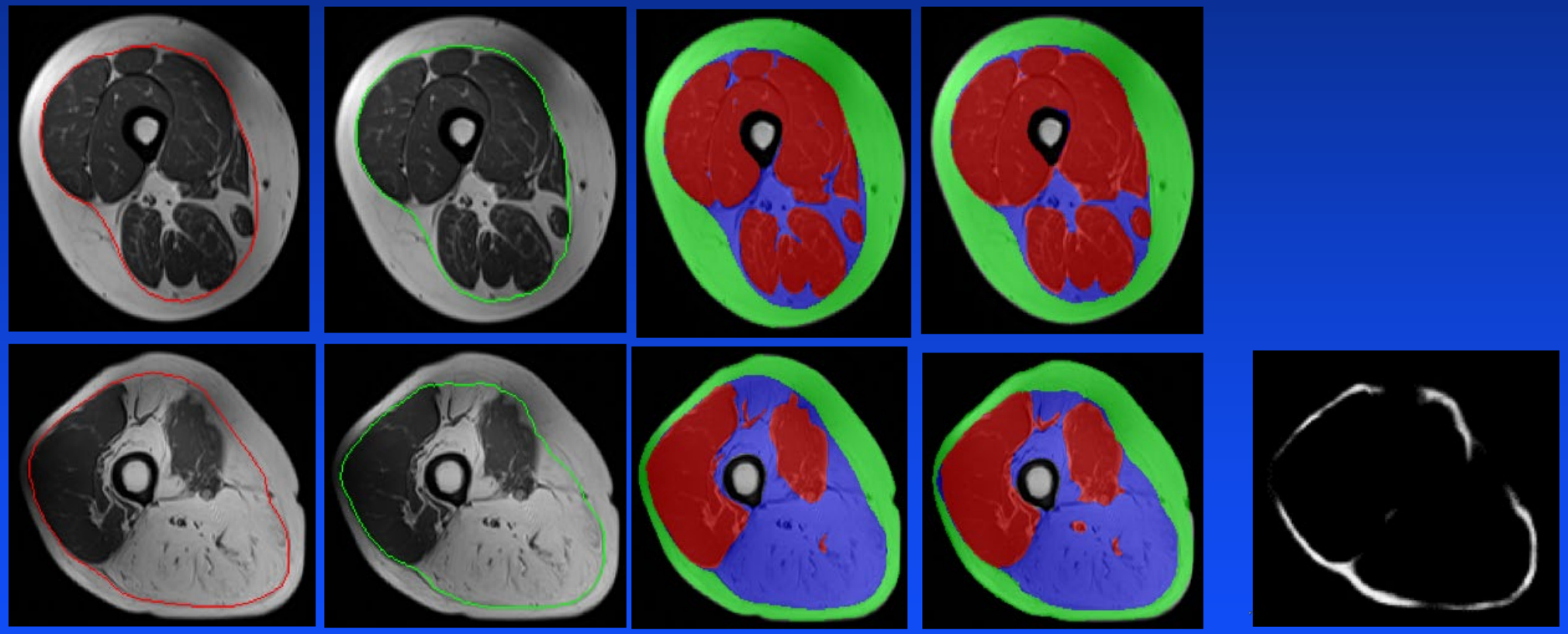

J Yao et al. MICCAI 2017

Sarcopenia Assessment: Muscle Segmentation

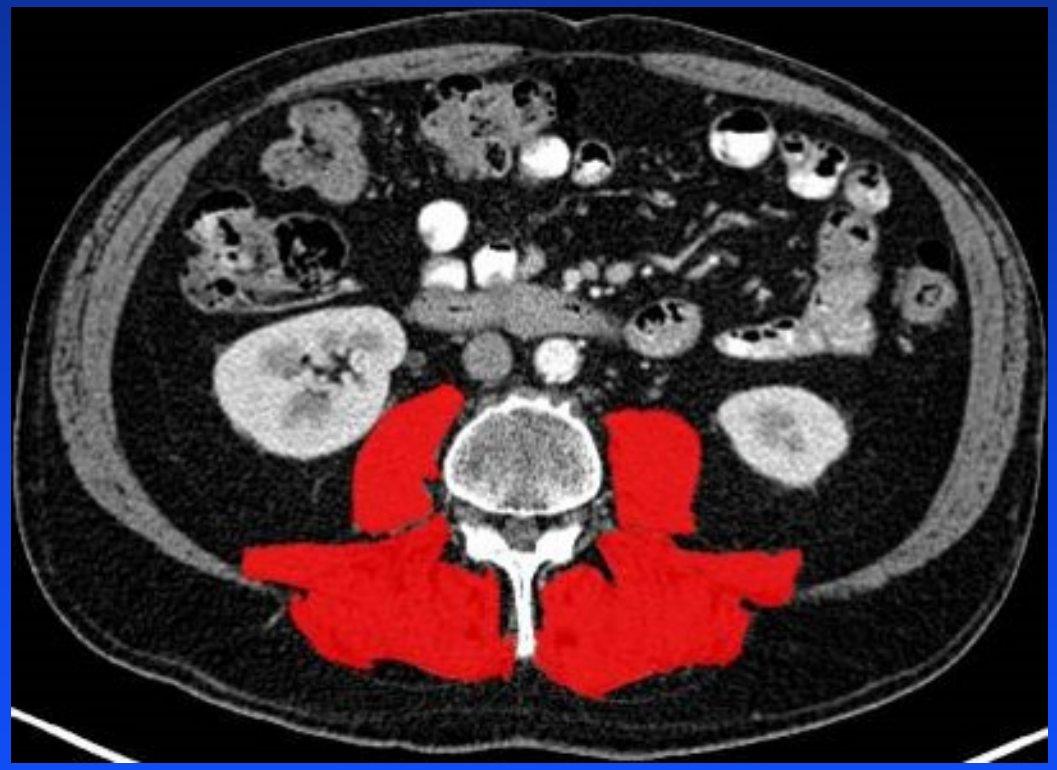

Burns et al. ARRS 2018

Tumor Growth Modeling



Day 0 | Day 168 | Day 720

(a) Ground truth of tumor growth at different time points.



Statistical Learning Prediction
Recall: 86.9%; Precision: 91.8%;
Dice: 89.3%; RVD: 5.2%

Model-Based Prediction [9]
Recall: 73.9%; Precision: 97.8%;
Dice: 84.2%; RVD: 27.9%

(b) Prediction at the third time point (Day 720).

L Zhang et al. MICCAI 2017

Data Mining Reports & Images

DISEASE ONTOLOGY

contains:
{retroperitoneal, mesenteric, lymph, nodes, hepatis}

Report:

…

Several small retroperitoneal mesenteric lymph nodes are seen.

The largest nodes are in the porta hepatis (series 6450, image 104)
(cannot form a bi-gram!) *(cannot form a bi-gram!)*
and measures 1.2 cm in maximal dimensions. It was seen previously

and is stable.

…

feed-forward convolutional neural network

$X \in R^{256\times256}$

$\bar{y} \in R^{2\times256}$

[retroperitoneal mesenteric]
[mesenteric lymph]
[lymph nodes]

HC Shin et al. CVPR 2015

Data Mining Reports & Images

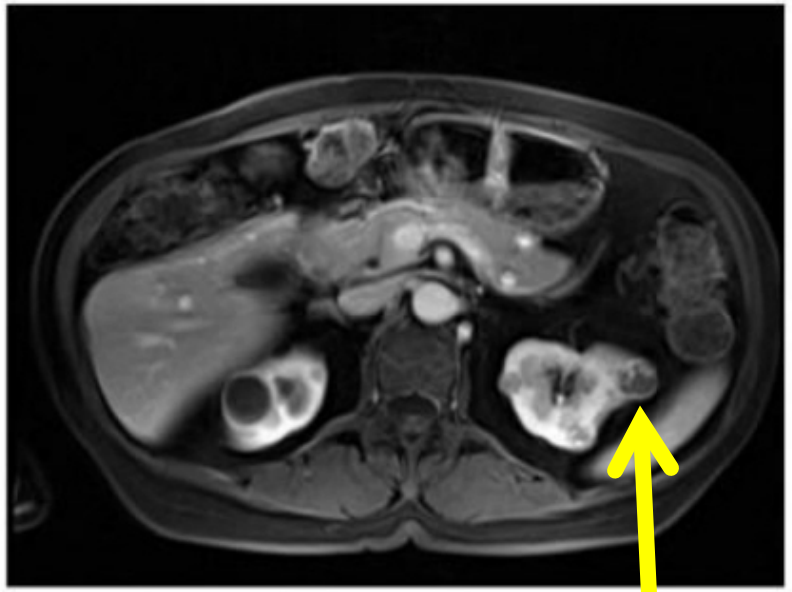

diameter
mass
kidney

avg distance: 0.33

"... and solid lobulated **mass** arises from the anterior lower pole of right **kidney** and measures 1.6 cm in **diameter** ..."

HC Shin et al. CVPR 2015 & JMLR 2016

Data Mining Reports & Images

Word	Frequency
liver	524
abdomen	337
enhancement	217
mass	198
lesion	168
lobe	161
adenopathy	119
lesions	109
segment	58
bulky	45

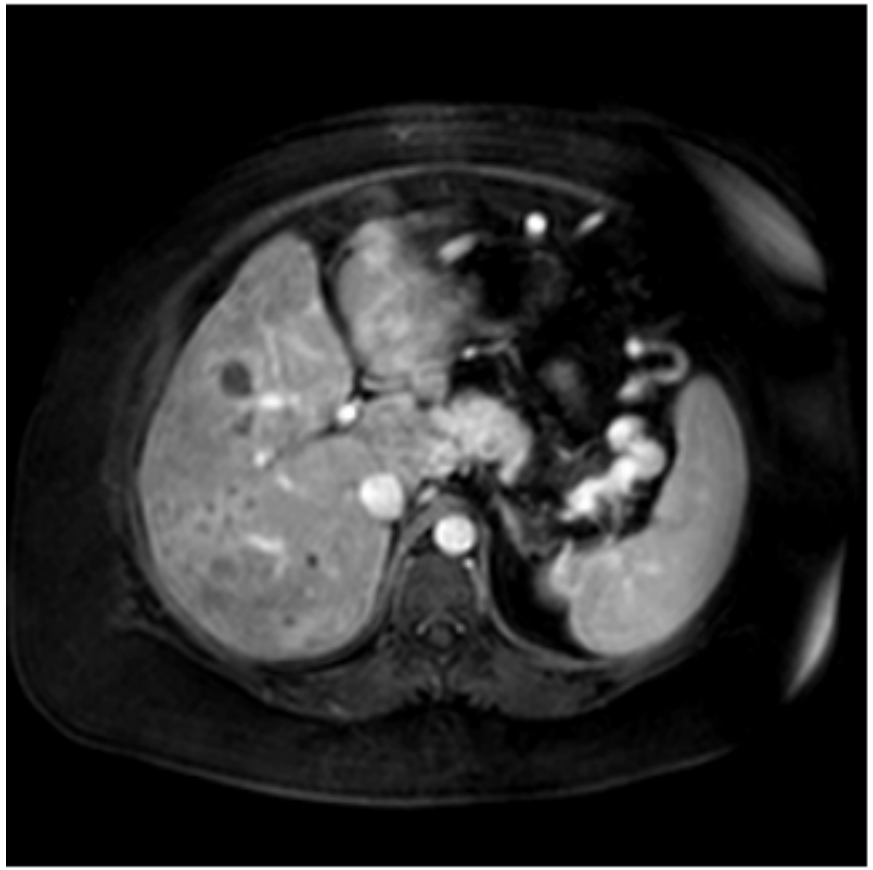

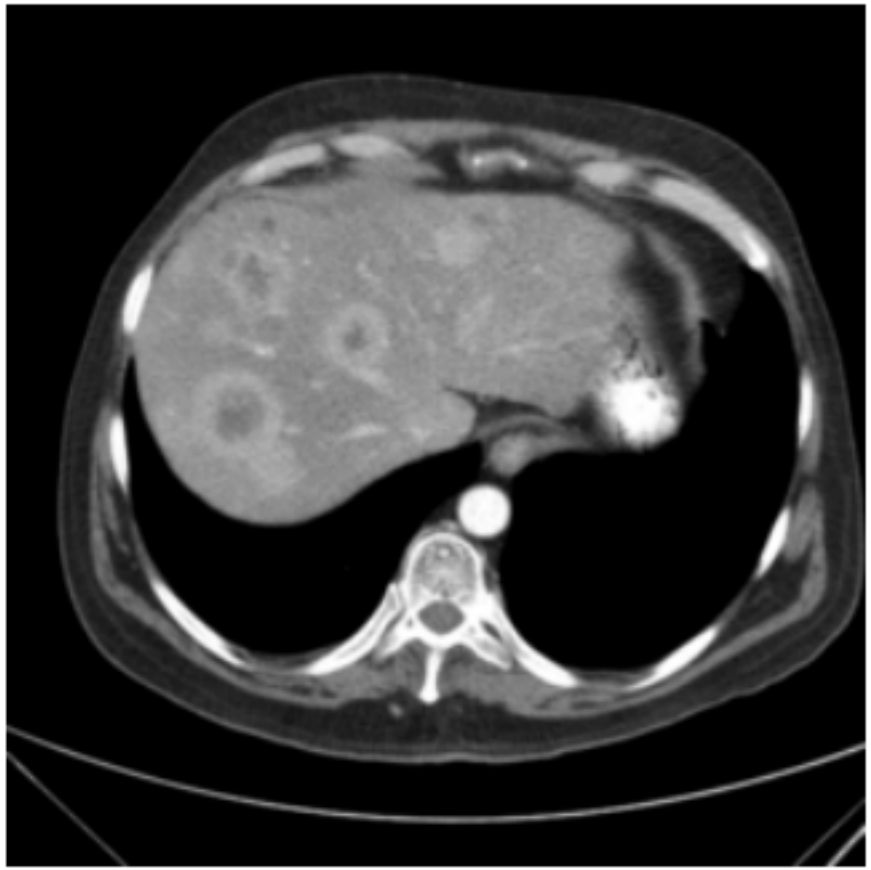

X Wang et al. WACV 2017

National Institutes of Health
Turning Discovery Into Health

Health Information | Grants & Funding | News & Events | Research & Training

Home » News & Events » News Releases

NEWS RELEASES

Media Advisory Wednesday, September 27, 2017

NIH Clinical Center provides one of the largest publicly available chest x-ray datasets to scientific community

The dataset of scans is from more than 30,000 patients, including many with advanced lung disease.

ChestX-ray8 Dataset

- https://nihcc.app.box.com/v/ChestXray-NIHCC
- “ChestX-ray8 Dataset”
- 112,120 frontal-view chest radiographs, 30,805 unique patients
- 42 GB
- Metadata for all images
- Bounding boxes for 1000 images

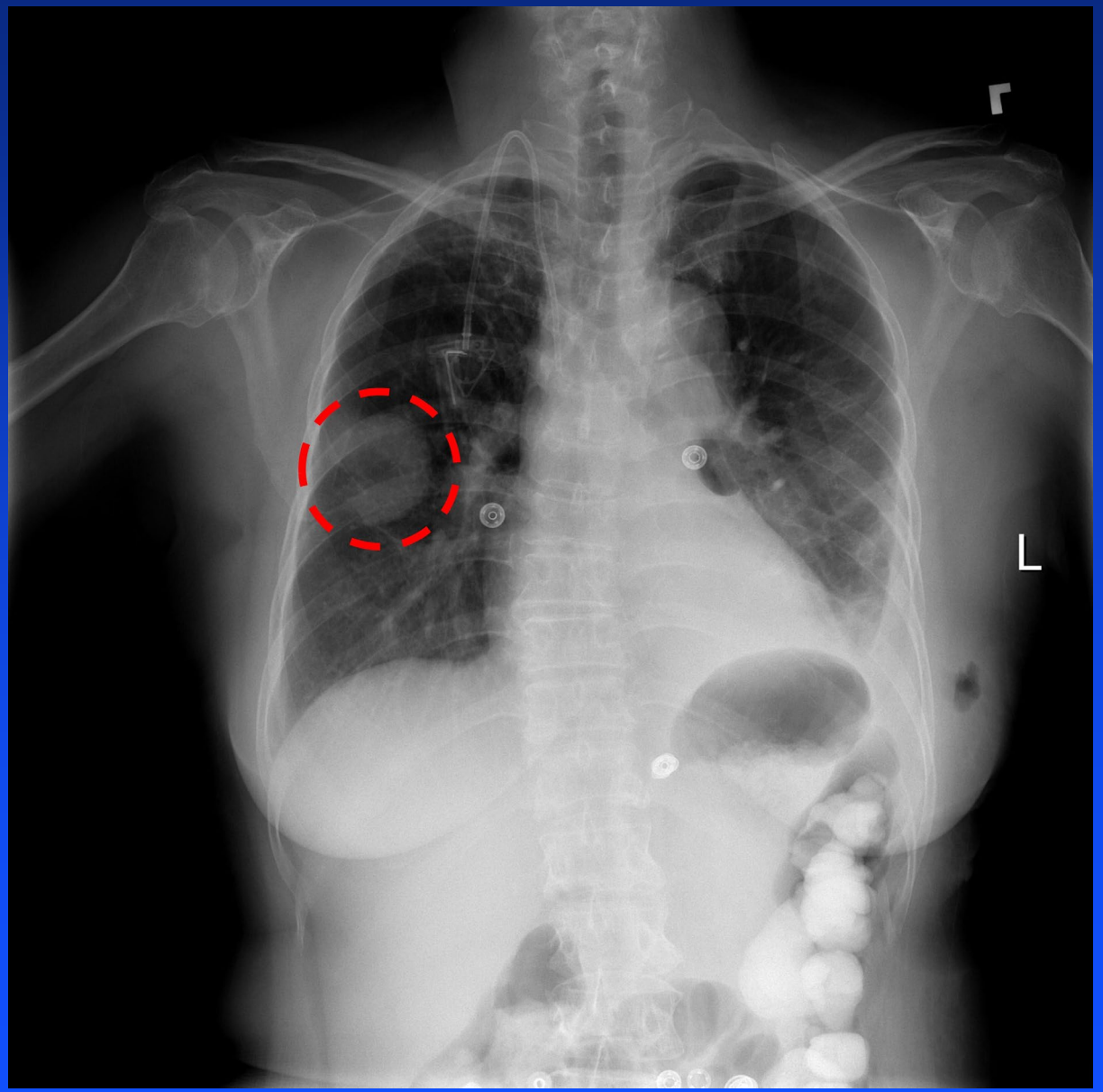

TieNet: Text-Image Embedding Network

Image sample cases	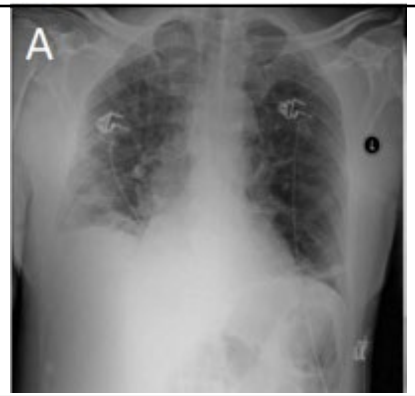	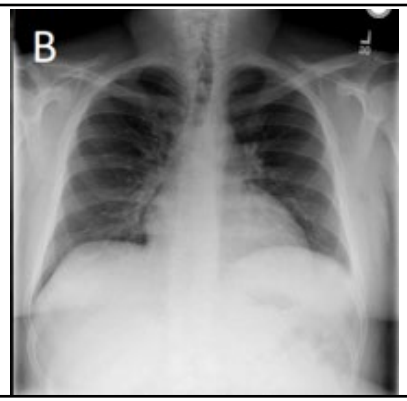	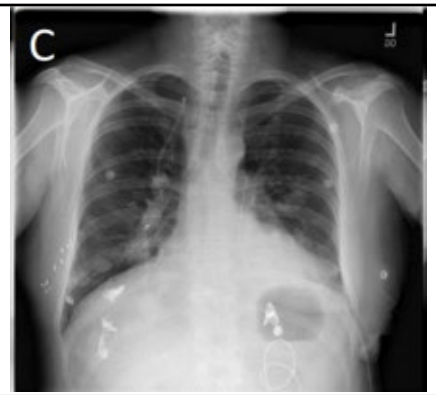	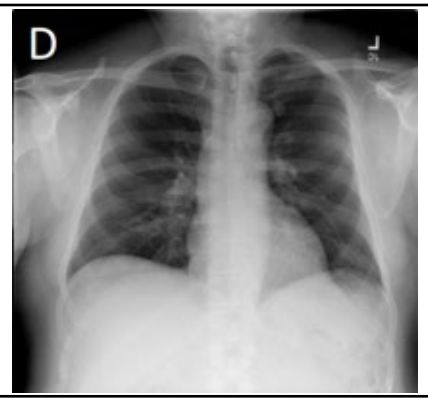
P	*Atelactasis* EFFUSION	*No finding*	*Nodule* PNEUMOTHORAX Mass Consolidation	MASS
Original report	findings : a single ap view of the chest demonstrates increasing bibasilar nterstitial opacities with decreased overall aeration . increasing blunting of right costophrenic angle .... impression : increasing bibasilar atelectasis with possible development of right pleural effusion.	Normal no evidence of lung infiltrate .	findings : heart and mediastinum unchanged . multiple lung nodules . evidence of recent left chest surgery with left chest tube in place . very small left apical pneumothorax . lungs unchanged , noevidence of acute infiltrates . impression : stable chest .	findings : large left suprahilar and infrahilar masses as well as the well circumscribed nodule the level of the aortic knob. the right infrahilar mass as well . no effusion . impression : metastatic lung disease .
Generated Report	findings : a single ap view of the chest demonstrates unchanged bilateral reticular opacities , consider atelectasis . continued left basilar atelectasis . no evidence of developing infiltrate . the cardiac and mediastinal contours are stable . impression : no evidence of developing infiltrate .	findings : pa and lateral views of the chest demonstrate lungs that are clear without focal mass , infiltrate or effusion . cardiomediastinal silhouette is normal size and contour . pulmonary vascularity is normal in caliber and distribution . impression : no evidence of acute pulmonary pathology	findings: pa and lateral views of the chest demonstrate unchanged bilateral chest tubes . again pulmonary nodules are seen on the right and cardiac silhouette unchanged . the cardiac and mediastinal contours are stable . impression : 1. bilateral masses and left lower lung field consolidation . 2.new bilateral lung masses .	comparison is to previous upright study of no significant interval change is seen in the appearance of the chest , the mediastinal soft tissue and pulmonary vascularity are stable . there are blastic bone lesions in the chest . bones , soft tissues are normal . the lung fields are clear . there are calcified lymph nodes in the left lower lung . impression : . sclerotic lesions in the left humeral , consistent with metastasis.

X Wang et al. CVPR 2018

Deep Lesion Dataset

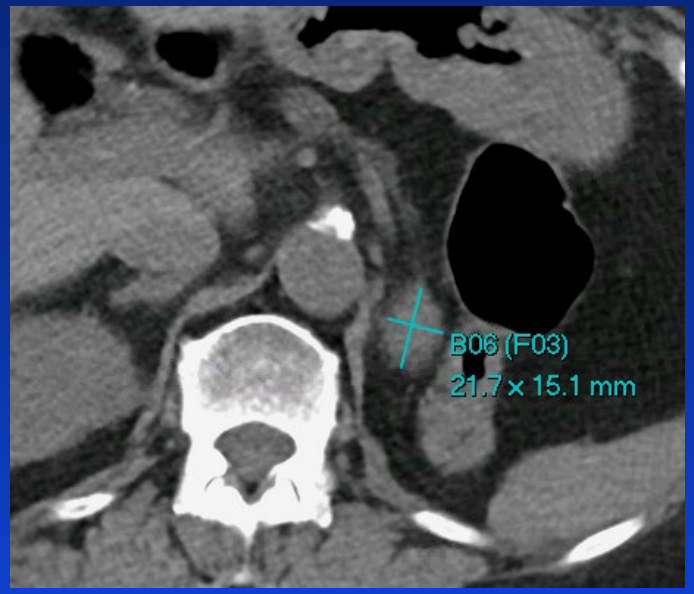

- 32,735 lesions
- 32,120 CT slices
- 10,594 studies
- 4,427 unique patients
- https://nihcc.box.com/v/DeepLesion

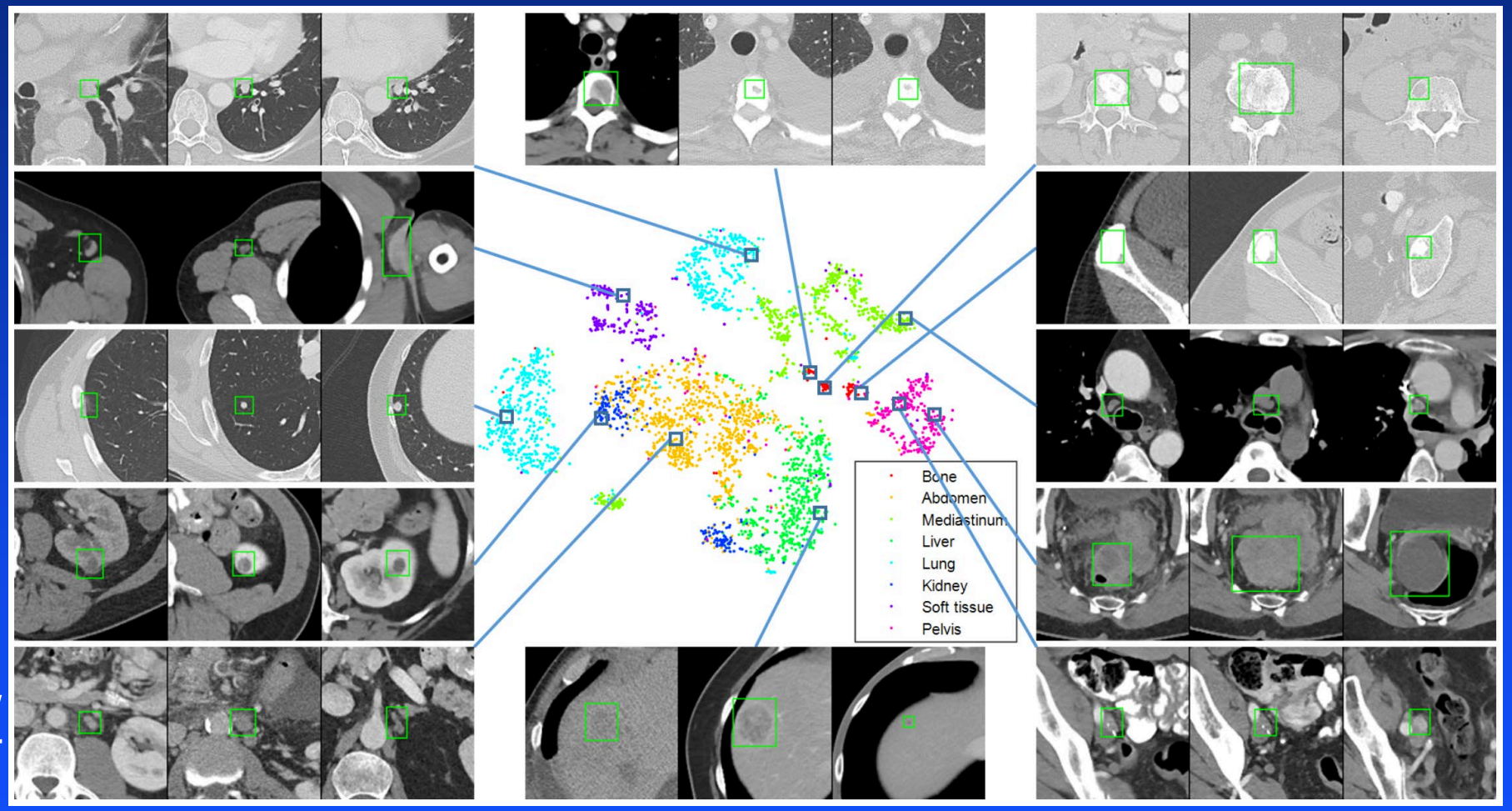

Yan et al. JMI 2018; CVPR 2018; RSNA 2018

Universal Lesion Detector

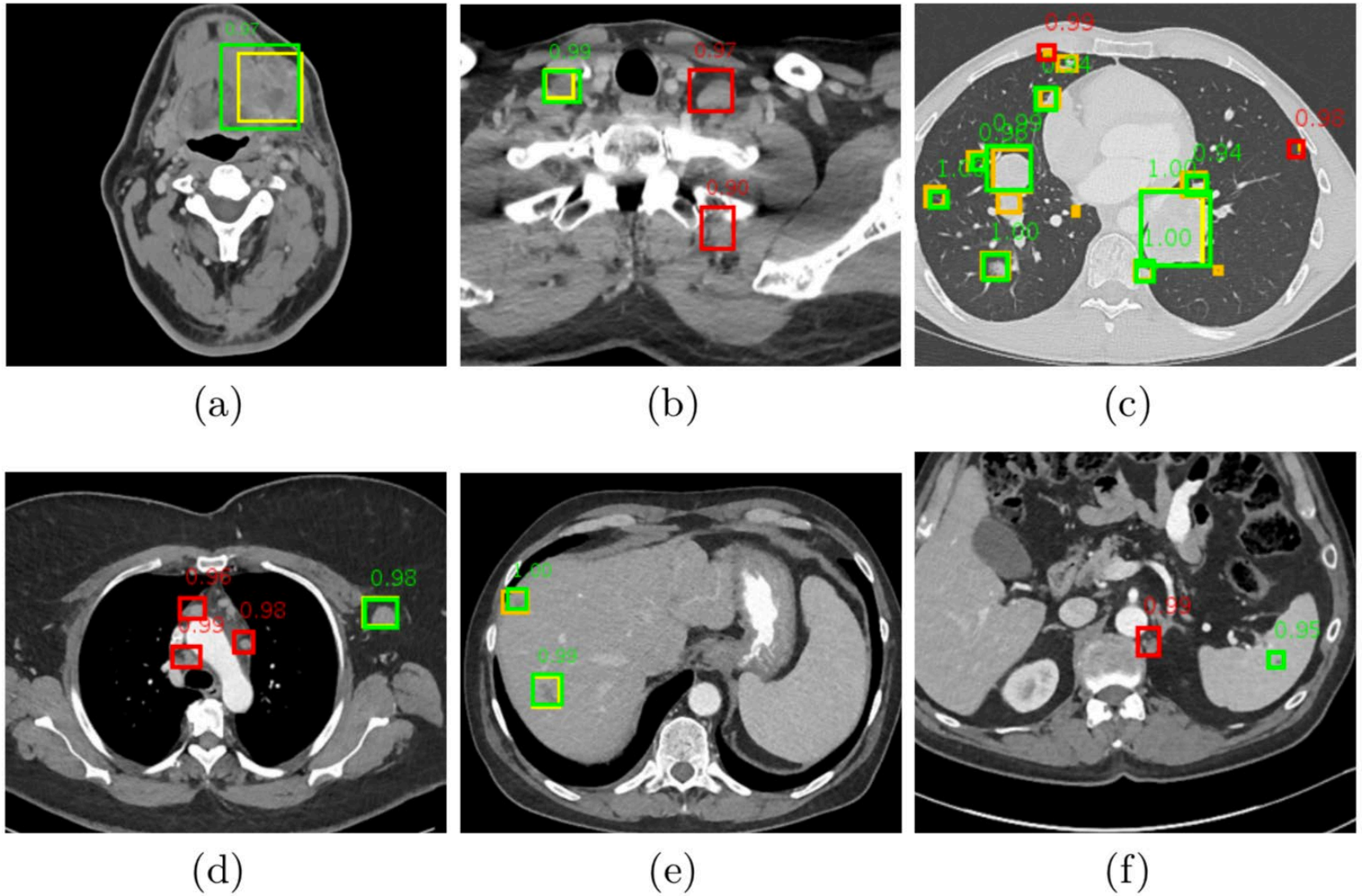

Yan et al. MICCAI 2018

Conclusions

- Rapid developments in AI ➡ Exciting time for medical imaging research and patient care
- NIH CC is a leader in AI in medical imaging
- NIH CC contributions to the AI research community are widely recognized and appreciated

Acknowledgments

- Le Lu
- Jack Yao
- Jiamin Liu
- Nathan Lay
- Hadi Bagheri
- Holger Roth
- Hoo-Chang Shin
- Xiaosong Wang
- Adam Harrison
- Ke Yan
- Ling Zhang
- Isabella Nogues
- Youbao Tang
- Yuxing Tang
- Nicholas Petrick
- Berkman Sahiner
- Joseph Burns
- Perry Pickhardt
- Mingchen Gao
- Daniel Mollura
- Baris Turkbey
- Peter Choyke
- Matthew Greer
- Brad Wood
- Jin Tae Kwak
- Ruida Cheng
- Jing Xiao
- Yifan Peng
- Zhiyong Lu
- CC
- NCI
- NLM
- NHLBI
- NIDDK
- NIAID
- FDA
- Mayo Clinic
- DOD
- U. Wisconsin
- NIH Fellowship Programs:
  - Fogarty
  - ISTP
  - IRTA
  - BESIP
  - CRTP
  - SIP
- Nvidia for GPU card donations

To Learn More …



www.cc.nih.gov/drd/summers.html

X Wang et al. RSNA 2016